

Case Study: Ropan Effect of Vranaropankar Churna in the Management of Shuddha Vrana:

A case study

Author: Dr. Umesh Abhiman Paikrao, PG Scholar, Department of Shalya Tantra.

Address: Ajwa building, patwardhan lote, tq.khed , Dist.Ratnagiri 415722

Mobile no.9860732383

Email: [umeshpaikrao9@Gmail.com]

Affiliation: MES Ayurved Mahavidyalaya Ghanekhunt Lote, Khed, Ratnagi

Co author: Dr. Ashok Pawar, associate professor, MS Shalyatantra

Affllation: MES Ayurved Mahavidyalaya. ghanekhunt Lote, Khed, Ratnagiri.

Abstract:

Vrana, or wound, is a common clinical condition extensively discussed in Ayurvedic texts. Among its various stages, Shuddha Vrana denotes a clean wound suitable for healing interventions. This case study presents the clinical outcome of a 28 year old female patient with a traumatic Shuddha Vrana on the lower limb, managed using Vranaropankar Churna, a classical Ayurvedic formulation. The formulation, composed of Panchavalkala and Shukti Churna, was applied locally on alternate days for 15 days. Wound healing was assessed using both objective and subjective parameters, including size reduction, pain relief, discharge, granulation tissue, and margin changes. By the end of the treatment, the patient exhibited significant wound contraction, absence of discharge and pain, and signs of complete healing (Roodha Vrana). This case highlights the therapeutic potential of Vranaropankar Churna in promoting wound healing and supports its use as an effective Ayurvedic intervention in the management of Shuddha Vrana.

Keywords: Shuddha vrana, Vranaropankar Churna, wound healing, Ropan Karma, Panchavalkal Churna, Shukti Churna.

Introduction:

Wound care (Vrana Chikitsa) is a vital part of Shalyatantra in Ayurveda, with detailed guidance given by Acharya Sushruta on the classification, pathology, and management of wounds. Shuddha Vrana refers to a clean, granulating wound free from infection, where healing interventions like Ropana Karma (healing measures) are most effective. Among the classical approaches, Avachurnana—the dusting of medicated powders is highlighted for its effectiveness in promoting healing.

In modern medicine, wound management often involves antiseptic or antibiotic preparations, which, despite their efficacy, may sometimes result in delayed healing, resistance, or side effects. Ayurvedic formulations offer natural, biocompatible alternatives that support healing through multiple mechanisms including anti-inflammatory, antimicrobial, and regenerative effects.

Vranaropankar Churna, a polyherbal formulation consisting of Panchavalkala (five astringent barks) and Shukti Churna (processed oyster shell), is designed to enhance wound healing through Ropana Karma.

These ingredients possess Kashaya Rasa, Sheeta Virya, and Kaphapitta Shamaka properties, promoting tissue regeneration and reducing inflammation.

This case study explores the successful application of Vranaropankar Churna in a 28 year old female patient with a Shuddha Vrana. The case demonstrated accelerated healing, suggesting that the formulation may serve as an effective Ayurvedic intervention in wound care.

Aim:

To evaluate the efficacy of Vranaropankar Churna in the management of Shuddha Vrana (clean wound) with respect to its Ropana Karma (wound healing effect).

Objective:

To assess the wound healing (Ropana) effect of Vranaropankar Churna in patients with Shuddha Vrana over a treatment period of 15 days.

Case report:

A 28 year old female patient with a clean wound on the right foot was included in the trial after meeting inclusion criteria. The patient received alternate-day application of Vranaropankar Churna for 15 days. Objective (wound size, wound perimeter) and subjective (pain, discharge, colour, margin and granulation) parameters were assessed on days 0, 5, 10, and 15.

Case presentation :

Name: classified

- Age/Gender: 28/F
- Complaint: Healing wound post trauma on the right lower leg since 6 days
- Past Medical History: No history of diabetes, immunocompromise, or bleeding disorders
- Size of Wound: 3 cm × 2.5 cm=10cm²
- Depth: <0.5 cm
- Site: Medial aspect of right foot

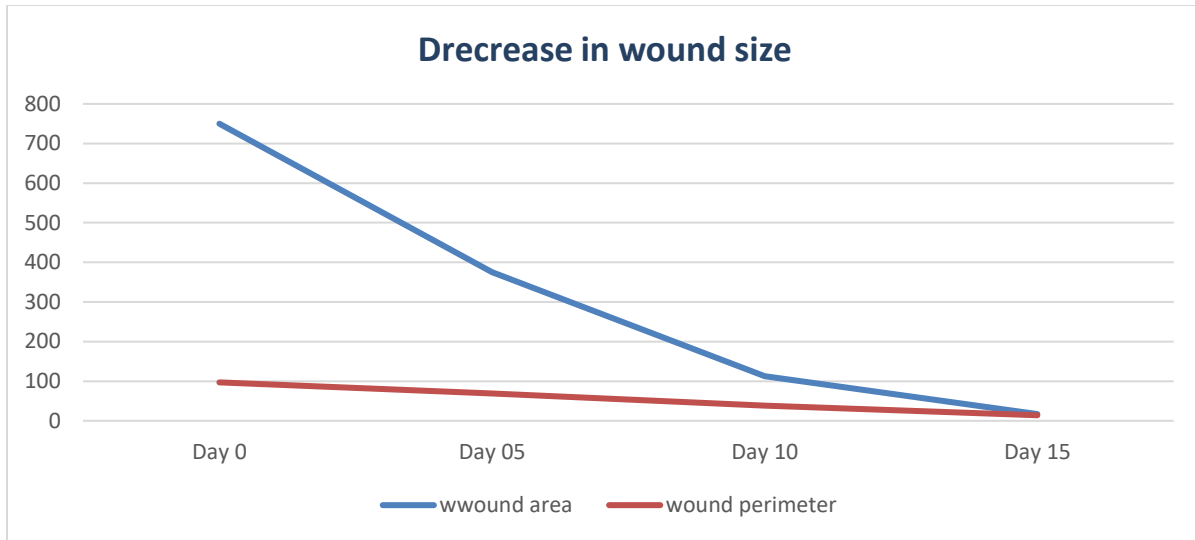
Intervention :

- Drug Applied: Vranaropankar Churna
- Mode: Local application via dusting
- Frequency: Alternate days for 15 days
- Oral Co-medication: Triphala Guggulu 2BID
- Follow-up Days: 0, 5, 10, and 15

Wound Assesment:

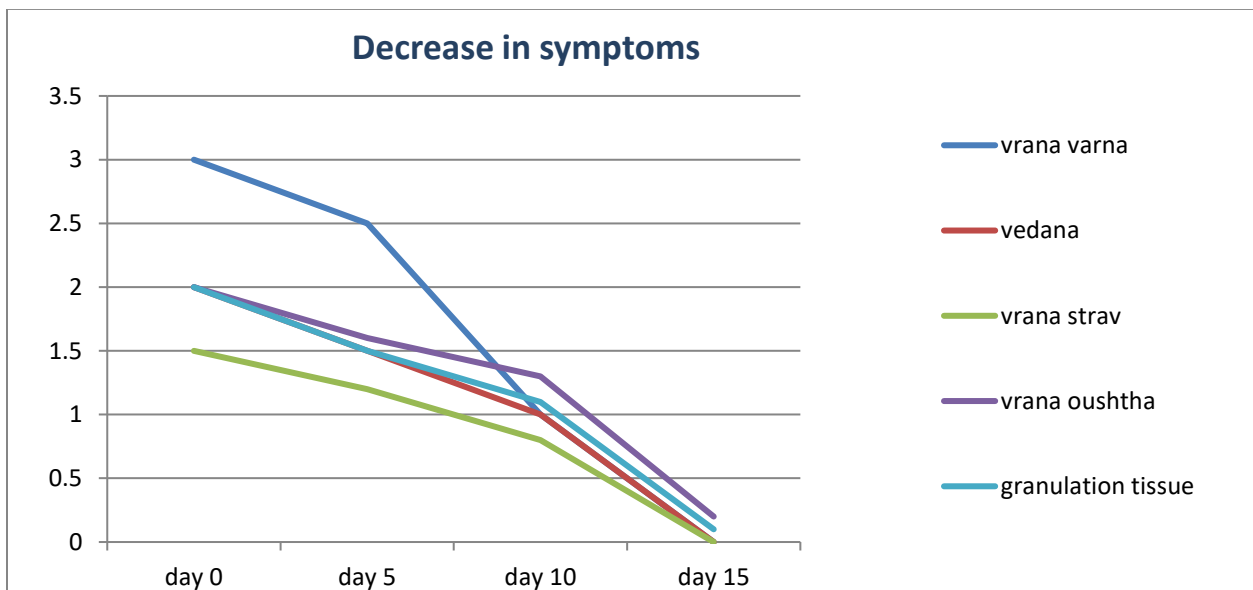
Objective Parameters:

Parameter	Day 0	Day 5	Day 10	Day 15
Wound Area in mm ²	750mm ²	375mm ²	113mm ²	17mm ²
Wound Perimeter in mm	97mm	69mm	38mm	14mm



Subjective Parameters :

Parameter	Day 0	Day 5	Day 10	Day 15
Vrana varna	Grade 3 Jivhatalabho	Grade 2 Shwetarakta	Grade 1 Kapotvarna	Grade 0 Twakasawarna
Vedana	Present	Mild	Absent	Absent
Vrana Strav	Grade 1 Lasika	Grade 0 Astrav	Grade 0 Astrav	Grade 0 Astrav
Vrana Oushtha	Grade 2 Atisthulam	Grade 1 Antasthir	Grade 1 Antasthir	Grade 0 Rudhavartamna
Granulation Tissue	Present	Present	Present	Absent



Result:

The clinical outcome of this case study showed a progressive and consistent healing response to the local application of Vranaropankar Churna over a 15-day treatment period.

Objective Findings:

The wound area reduced significantly from approximately 750 mm² on Day 0 to 17 mm² on Day 15.

The wound perimeter also reduced from 97mm to 14mm, indicating considerable wound contraction and healing.

Subjective Findings:

Vrana Varna (wound color) improved from Grade 3 – Jivhatalabho to Grade 0 – Twakasawarna, denoting complete healing.

Vedana (pain), initially present, was completely absent by Day 10.

Vrana Strava (discharge) subsided by Day 5 and remained absent.

Vrana Oushtha (wound margins) normalized from Grade 2 – Atisthulam to Grade 0 – Rudhavartmana by Day 15.

Granulation tissue, which was present up to Day 10, was fully resolved by Day 15, indicating transition to Roodha Vrana (healed wound).

No adverse effects were observed during the course of treatment.

These results suggest that Vranaropankar Churna is effective in accelerating the wound healing process in Shuddha Vrana, both symptomatically and in terms of measurable wound parameters.

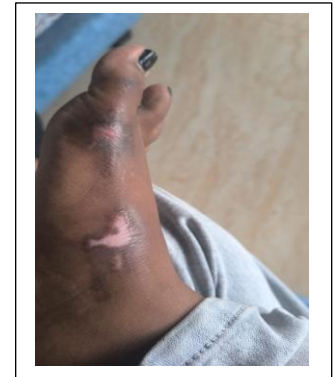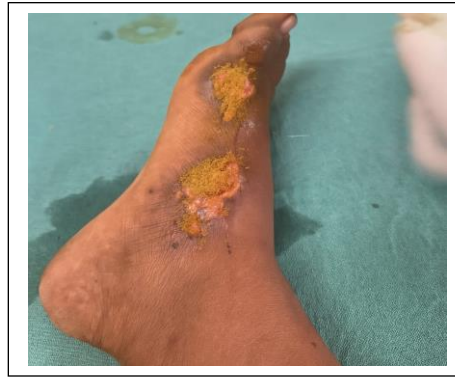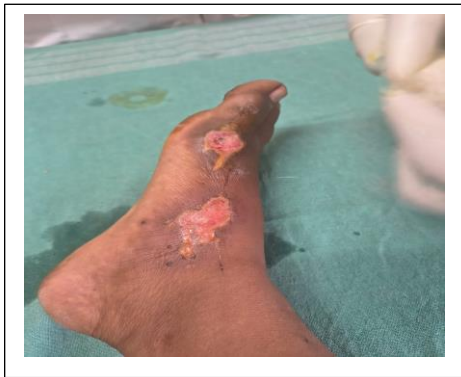Discussion:

This case study evaluated the Ropana (healing) potential of Vranaropankar Churna, a classical Ayurvedic formulation, in the management of a Shuddha Vrana in a 28 year old female patient. The formulation, rich in astringent (Kashaya), cooling (Sheeta), and anti-inflammatory herbs such as Panchavalkala and Shukti Churna, was applied locally on alternate days for 15 days, accompanied by oral administration of Triphala Guggulu. Objective parameters revealed a significant reduction in wound dimensions. The wound area decreased from approximately 750 mm² on Day 0 to 17 mm² by Day 15. Similarly, the wound perimeter reduced from 97 mm to 14 mm over the same period. This marked contraction suggests effective granulation and epithelialization promoted by the Churna's pharmacological actions such as antimicrobial, antioxidant, and tissue-regenerative effects. Subjective parameters further validated clinical improvement. The wound color (Vrana Varna) progressed from Grade 3 (Jivhatalabho) to Grade 0 (Twakasawarna), indicating a shift from granulating to fully healed tissue. Pain (Vedana), initially present, was completely absent by Day 10. Discharge (Vrana Strava) ceased by Day 5, and wound margins (Vrana Oushtha) normalized from inflamed to adherent by Day 15. Granulation tissue, a marker of active healing, was noted until Day 10 and had resolved by Day 15—indicating transition to the Roodha Vrana stage. The gradual and consistent improvement in both subjective and objective parameters underscores the potential of Vranaropankar Churna as an effective Ayurvedic wound-healing agent. The outcomes align with the Ropana Karma principles described in Sushruta Samhita, demonstrating that classical formulations can complement or even substitute conventional topical therapies in selected cases. These

results support the inclusion of Vranaropankar Churna in clinical practice, particularly for managing Shuddha Vrana in a safe, natural, and holistic manner. Further controlled studies with larger sample sizes are recommended to validate these findings

Conclusion:

The present case study demonstrates the significant wound healing potential of Vranaropankar Churna in the management of Shuddha Vrana. Over a 15-day period, the patient showed consistent and measurable improvement in both objective and subjective clinical parameters, including marked reduction in wound size, complete cessation of discharge, relief from pain, normalization of wound margins, and restoration of healthy skin coloration (Twakasawarna). The findings indicate that Vranaropankar Churna, when used as a local application, effectively promotes Ropana Karma (wound healing), aligning with the Ayurvedic principles described by Acharya Sushruta. Its astringent, anti-inflammatory, antimicrobial, and tissue-regenerative properties contributed to accelerated healing, without any observed adverse effects. In conclusion, Vranaropankar Churna emerges as a safe, effective, and affordable Ayurvedic alternative for managing clean wounds. This case supports its integration into standard wound care protocols, especially in settings where natural, side-effect-free therapies are preferred. However, further clinical trials with larger sample sizes and comparative analyses are warranted to strengthen the generalizability of these results.



References:

1. Sharma PV, editor. Sushruta Samhita of Acharya Sushruta. Sutrasthana, Chapter 22, Verse 7. Varanasi: Chaukhambha Visvabharati; 2018.

2. Sharma PV, editor. Sushruta Samhita of Acharya Sushruta. Chikitsasthana, Chapter 1, Verse 7. Varanasi: Chaukhambha Visvabharati; 2018.
3. Tripathi B, editor. Chakradatta of Chakrapani. Vranashotha Chikitsa Prakarana, Chapter 44, Verse 40. Varanasi: Chaukhambha Surbharati Prakashan; 2016.
4. Murugesu S, Selamat J, Perumal V. Phytochemical constituents and wound healing activity of medicinal plants: A review. *Plants (Basel)*. 2021;10(12):2749.
5. Yadav RK, Nandy BC, Maity S, Mukherjee A. Wound healing activity of medicinal plants: A review. *Pharmacogn Rev*. 2015;9(17):73–80.
6. Vasudevan M, Gunnam KK, Parle M. Antinociceptive and anti-inflammatory properties of herbal formulations used in wound management. *J Ethnopharmacol*. 2007;109(2):264–270.
7. Bhat KS, Vishwesh BN, Sahu M, Shukla VK. A clinical study on the effect of Panchavalka Kashaya in wound healing. *AYU*. 2014;35(2):135–140.
8. Shinde PS, Killedar RS, Santosh YM, et al. Evaluation of Ayurvedic topical formulations in Vrana Ropana. *Ann Ayurveda Med*. 2020;9:98–107.
9. Dwivedi R, editor. Ashtanga Hridaya of Vagbhata. Sutrasthana, Chapter 25. Varanasi: Chaukhambha Krishnadas Academy; 2017.
10. Acharya JT, editor. Charaka Samhita. Chikitsasthana, Chapter 25. Varanasi: Chaukhambha Orientalia; 2019.
11. Kumar V, Abbas AK, Aster JC. Robbins and Cotran Pathologic Basis of Disease. 10th ed. Philadelphia: Elsevier; 2021.
12. Guo S, Dipietro LA. Factors affecting wound healing. *J Dent Res*. 2010;89(3):219–229.
13. Boateng J, Catanzano O. Advanced therapeutic dressings for effective wound healing— A review. *J Pharm Sci*. 2015;104(11):3653–3680.
14. Lodhi S, Singhai AK. Wound healing effect of flavonoid-rich fractions from medicinal plants. *Asian Pac J Trop Med*. 2013;6(9):747–754.
15. Upadhyay OP, Pandey K. Role of Kashaya Rasa drugs in Vrana Ropana. *Int J Ayurveda Res*. 2011;2(4):220–224.
16. World Health Organization. WHO guidelines on good herbal processing practices for herbal medicines. Geneva: WHO; 2018.
17. Shukla VK, Gupta SK. Ayurvedic concepts of wound healing and their relevance in modern surgery. *J Ayurveda Integr Med*. 2010;1(4):231–235.